

Keratectasia After LASIK Versus PRK

Mohammad Ali Javadi, MD; Mehrdad Mohammadpour, MD;
Hossein Mohammad Rabei, MD

ABSTRACT

PURPOSE: To report a case of keratectasia in a patient who underwent LASIK in the right eye and photorefractive keratectomy (PRK) in the left eye for correction of compound myopic astigmatism.

METHODS: A 30-year-old man underwent LASIK in the right eye and PRK in left eye for refraction of $-1.75 -1.50 \times 48^\circ$ and $-1.00 -1.75 \times 100^\circ$, respectively. Preoperative corneal thickness was $447 \mu\text{m}$ in the right eye and $446 \mu\text{m}$ in the left eye.

RESULTS: Postoperative corneal thickness decreased to $341 \mu\text{m}$ and $384 \mu\text{m}$ in the right and left eye, respectively. Uncorrected visual acuity in the left eye was 20/20, but the right eye developed keratectasia, which led to severe visual loss (20/400).

CONCLUSIONS: Photorefractive keratectomy may be better than LASIK for ablative refractive surgery for low myopic astigmatism in eyes with low central corneal thickness. [*J Refract Surg.* 2006;22:xxx-xxx.]

Laser in situ keratomileusis (LASIK) has become a popular corneal refractive procedure. However, lamellar dissection of corneal layers in LASIK can result in complications, which have been reported in 0.3% to 10% of procedures.¹ Most flap complications, such as epithelial trauma, incomplete flaps, buttonholes, wrinkles, and flap displacement occur intraoperatively.¹

Corneal ectasia is a serious late complication of ablative refractive procedures. A review of the literature reveals >60 cases of keratectasia after LASIK, and at least 2 cases following photorefractive keratectomy (PRK).²⁻⁵

We describe a patient who underwent LASIK in the

From the Department of Ophthalmology, Labbafinejad Medical Center, Ophthalmic Research Center, Shaheed Beheshti University of Medical Sciences (Javadi, Mohammadpour); and the Department of Ophthalmology, Imam Hossein Hospital, Ophthalmic Research Center, University of Medical Sciences (Rabei), Tehran, Iran.

The authors have no proprietary interest in the materials presented herein.

Correspondence: Mohammad Ali Javadi, MD, Dept of Ophthalmology, Labbafinejad Medical Center, Ophthalmic Research Center, Shaheed Beheshti University of Medical Sciences, 9th Boostan, Pasdaran Ave, Tehran, Iran 16666. Tel: 98 21 222 19876; Fax: 98 21 22562138; E-mail: ma_javadi@yahoo.com

Received: September 13, 2005

Accepted: March 8, 2006

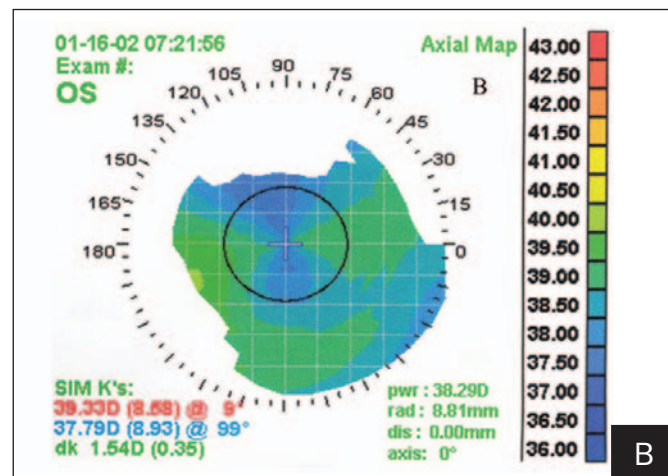
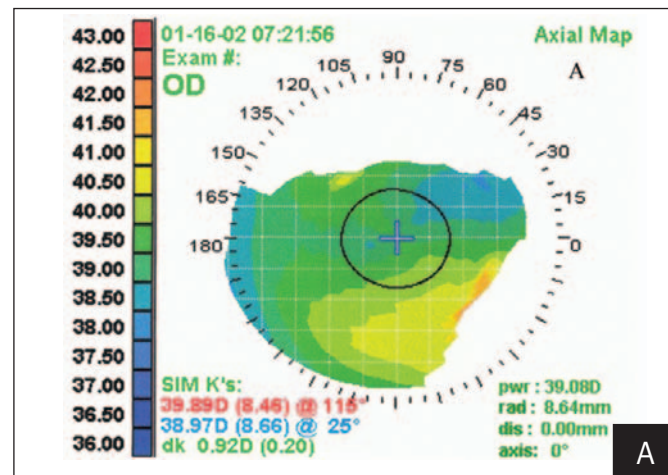


Figure 1. A) Preoperative topography of the right eye shows non-orthogonal with-the-rule astigmatism with inferonasal steepening. B) Preoperative topography of the left eye shows orthogonal against-the-rule astigmatism.

right eye and PRK in the left eye for correction of similar amounts of compound myopic astigmatism, but only the right eye developed keratectasia.

CASE REPORT

A 30-year-old man with myopic astigmatism underwent refractive surgery. Preoperative best spectacle-corrected visual acuity (BSCVA) was 20/25 in both eyes with refraction of $-1.75 -1.50 \times 48^\circ$ in the right eye and $-1.00 -1.75 \times 100^\circ$ in the left eye. Preoperative central corneal thickness was $447 \mu\text{m}$ in the right eye and $446 \mu\text{m}$ in the left eye with ultrasound pachymetry (NIDEK, Gamagori, Japan). Simulated keratometric (SimK) readings with TMS-I, were $39.8@115/38.9@25^\circ$ in the right eye and $39.3@9^\circ/37.7@99^\circ$ in the left eye. Topography revealed non-orthogonal asymmetric bow-tie with-the-rule astigmatism with an inferonasal steepening equal to 0.92 diopters (D) in the right eye and orthogonal symmetric against-the-rule astigmatism equal to 1.54 D in the left eye (Fig 1). The topo-

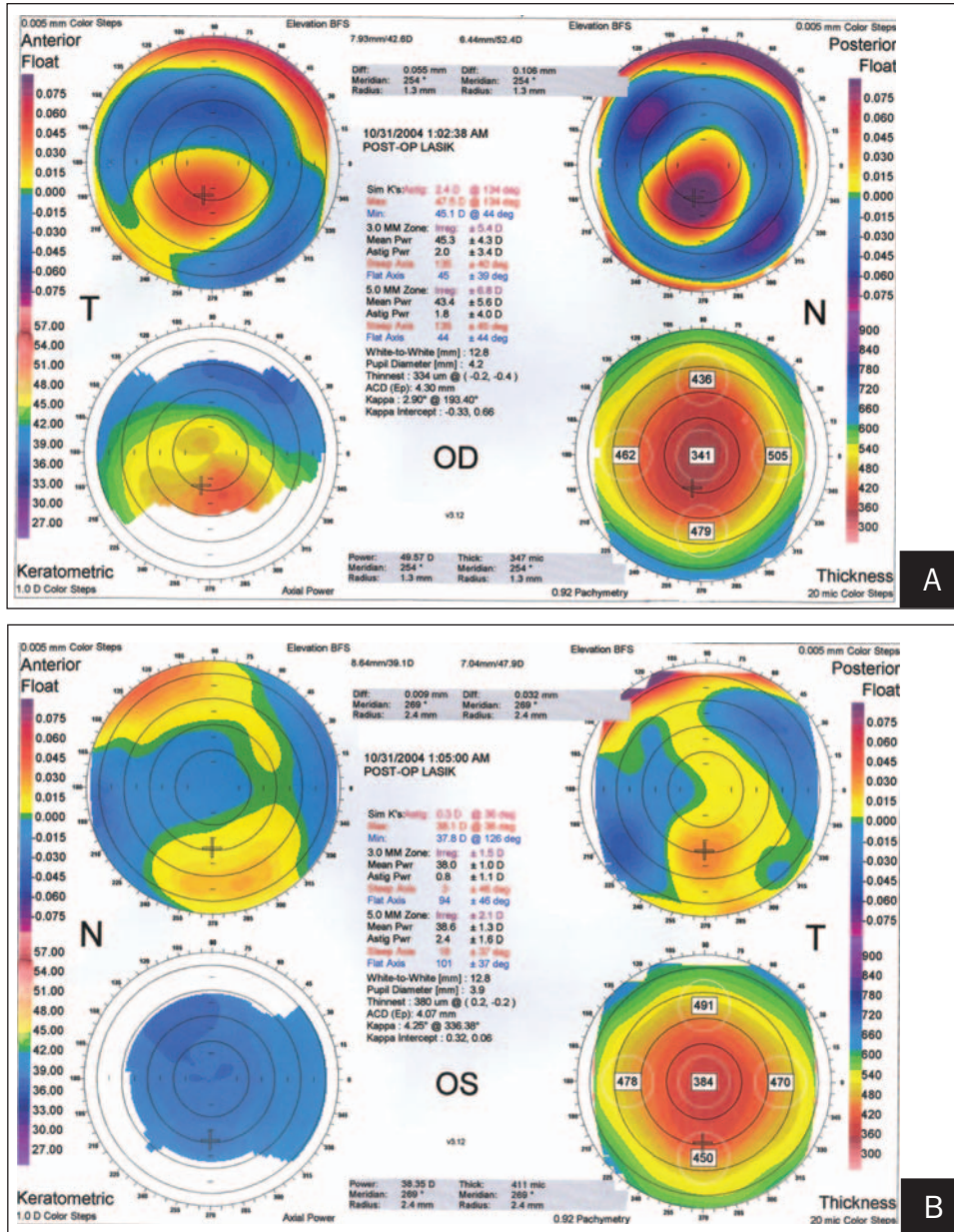


Figure 2. A) Orbscan of the right eye 33 months after LASIK shows advanced keratectasia. B) Orbscan of the left eye 21 months after PRK. Despite significant thinning of the central cornea, keratectasia has not developed and the cornea has a flat, oblate pattern.

graphic pattern of the right eye may be seen in patients with forme fruste keratoconus.

Uneventful LASIK was performed in the right eye in February 2002 with the NIDEK EC-5000 excimer laser with an ablation zone of 6 mm and transition zone of 7 mm with calculated depth of 50.3 μm. Intended flap thickness was 130 μm with the Moria M2 microkeratome (Moria, Antony, France). One month after LASIK, central corneal thickness was 403 μm. Best spectacle-corrected visual acuity was 20/20 with manifest refraction of plano -0.50 × 50°. In February 2003, the patient underwent PRK in the left eye by the same surgeon.

Visual acuity in the right eye gradually decreased 1 year after surgery, and in October 2003 it was

20/200 with -5.50 -2.50 × 54°. Orbscan pachymetry (Bausch & Lomb, Rochester, NY) showed central corneal thickness of 402 μm with correction factor of 0.92 and the topographic map revealed SimK readings of 43.7@157°/40.9@67° in the right eye.

The patient was referred to our center in November 2004. Uncorrected visual acuity (UCVA) was 20/400 in the right and 20/20 in the left eye. Best spectacle-corrected visual acuity was 20/200 in the right eye with -8.50 -2.25 × 26°. Slit-lamp examination demonstrated significant thinning and protrusion of the right cornea similar to the pattern that would be seen in keratoconus. Orbscan showed that central corneal thickness was 341 μm in the right eye and 384 μm in the left

eye. Simulated keratometry was 47.5@134°/45.1@44° in the right eye and 38.1@36°/37.8@126° in the left eye. The irregularity was ± 5.4 D in the right eye and ± 1.5 D in the left eye. The anterior float also revealed significant steepening of the right cornea. The posterior float showed significant intrusion of the posterior surface of the cornea in the right eye. The topographic map of the left eye showed an oblate pattern, which is usually expected after uneventful ablative refractive surgery for myopia (Fig 2).

DISCUSSION

One serious complication of LASIK is progressive corneal thinning and ectasia. This phenomenon has been termed progressive keratectasia after LASIK and has been reported to occur 1 week to >1 year after surgery.⁵

The pathogenesis of this condition is not well understood. Hypotheses include biomechanical corneal alterations, chronic disease process in predisposed individuals, or a combination of both.

Disruption of the anterior corneal lamellae due to creation of a LASIK flap and further disruption of central corneal lamellar continuity by excimer laser ablation appears to weaken corneal architecture. The weakened cornea progressively protrudes and thinning gradually becomes worse, leading to iatrogenic keratectasia.⁶

To prevent keratectasia, it is important to preserve at least 250 μm in the central stromal bed after ablation, although a more conservative approach would be to preserve at least half of the original corneal stromal thickness.⁷ It is also prudent to avoid LASIK in corneas thinner than 500 μm centrally. However, these guidelines may not completely avoid keratectasia after LASIK. Ou et al⁸ reported that 28 of 57 keratectasia cases after LASIK had residual stromal bed thickness >250 μm . Actual flap thickness may be more or less than intended and may vary considerably (± 80 μm) using a specific microkeratome. Corneal flap thickness is also related to corneal curvature, suction rate, and speed of microkeratome movement.⁸ Although we do not know the actual flap thickness and residual stromal bed in the right eye, but as intended flap thickness was 130 μm and ablation depth was 50 μm , the residual stromal bed would have been 267 μm , which is more than the usually accepted amount (250 μm).

The upper limit of myopia suitable for treatment by LASIK has been set at 12.0 D,⁶⁻⁸ however, keratectasia has been noted in eyes treated for much lower amounts of myopia from -4.0 to -7.0 D.⁹ In some eyes, corneal topographic abnormalities were detected preoperatively, consisting primarily of inferior corneal steepen-

ing.^{8,9} Eyes in which such changes are unaccompanied by refractive instability, increased astigmatism, corneal thinning, and other slit-lamp features of keratoconus have been termed forme fruste keratoconus.⁶

The major difference in the surgical technique of PRK and LASIK is the creation of a corneal flap in the latter, which may be the most important factor causing corneal destabilization. The flap is considered more important than excimer ablation depth, and the deeper stroma is believed to have less biomechanical strength than the anterior corneal layers. Reports indicate good intermediate and long-term refractive outcomes and corneal stability after PRK in eyes with suspected keratoconus, indicating that PRK may have less effect on corneal biomechanical properties.³⁻⁵ There are fewer reports of keratectasia after PRK as compared to LASIK. A study of the forward corneal shift seen after PRK using scanning-slit corneal topography concludes that these changes stabilize 6 months after surgery.³

Risk factors for postoperative keratectasia include age, higher myopic correction, less residual stromal thickness, larger ablation zone, irregular corneal thickness, abnormal corneal topography, and pre-existing corneal ectasia.¹⁻⁵

Although in this case the amount of refractive error was comparable in the right and left eyes, keratectasia occurred only in the right eye (which had undergone LASIK). This patient had preoperative central corneal thickness <500 μm , non-orthogonal asymmetric bow-tie astigmatism and inferonasal steepening in the right eye, and preoperative BSCVA of 20/25 in both eyes. These findings may be consistent with forme fruste keratoconus, which was more prominent in the right eye. This is the second report of a patient who underwent LASIK in one eye and PRK in the other eye for correction of similar amounts of compound myopic astigmatism and developed keratectasia only in the LASIK-operated eye.¹⁰

Photorefractive keratectomy may be a safer alternative to LASIK in eyes with low myopic astigmatism and relatively thin corneas. This may be due to the lack of flap creation, a factor that may weaken the anterior corneal structure and subsequently lead to keratectasia.

REFERENCES

1. Jacobs JM, Taravella MJ. Incidence of intraoperative flap complications in laser in situ keratomileusis. *J Cataract Refract Surg.* 2002;28:23-28.
2. Pallikaris IG, Kymionis GD, Astyrakakis NI. Corneal ectasia induced by laser in situ keratomileusis. *J Cataract Refract Surg.* 2001;27:1796-1802.
3. Bilgihan K, Ozdek SC, Konuk O, Akata F, Hasanreisoglu B. Results of photorefractive keratectomy in keratoconus suspects at 4 years. *J Refract Surg.* 2000;16:438-443.
4. Lee JB, Kim JS, Choe C, Seong GJ, Kim EK. Comparison of two

- procedures: photorefractive keratectomy versus laser in situ keratomileusis for low to moderate myopia. *Jpn J Ophthalmol.* 2001;45:487-491.
5. Comaish IF, Lawless MA. Progressive post-LASIK keratectasia: biomechanical instability or chronic disease process? *J Cataract Refract Surg.* 2002;28:2206-2213.
 6. Seiler T, Quurke AW. Iatrogenic keratectasia after LASIK in a case of forme fruste keratoconus. *J Cataract Refract Surg.* 1998;24:1007-1009.
 7. Argento C, Cosentino MJ, Tytiun A, Rapetti G, Zarate J. Corneal ectasia after laser in situ keratomileusis. *J Cataract Refract Surg.* 2001;27:1440-1448.
 8. Ou RJ, Shaw EL, Glasgow BJ. Keratectasia after laser in situ keratomileusis (LASIK): evaluation of the calculated residual stromal bed thickness. *Am J Ophthalmol.* 2002;134:771-773.
 9. Amoils SP, Deist MB, Gous P, Amoils PM. Iatrogenic keratectasia after laser in situ keratomileusis for less than -4.0 to -7.0 diopters of myopia. *J Cataract Refract Surg.* 2000;26:967-977.
 10. Rao SK, Srinivasan B, Sitalakshmi G, Padmanabhan P. Photorefractive keratectomy versus laser in situ keratomileusis to prevent keratectasia after corneal ablation. *J Cataract Refract Surg.* 2004;30:2623-2628.

AUTHOR QUERIES

Please verify phone number.

Please verify email address.

In the second paragraph you state, “A review of the literature reveals >60 cases of keratectasia after LASIK, and at least 2 cases of PRK.²⁻⁵” Which specific references (2, 3, 4, and/or 5) report on the 2 cases after PRK?

Please provide the specific model of the NIDEK ultrasound pachymeter.

Please provide manufacturer information for TMS-I.

Please verify the the “@” is the correct symbol to use for the SimK readings.

Please clarify what is meant by “a specific microkeratome” in the following sentence. Do you mean to say the flap thickness varies depending upon the microkeratome used?

Actual flap thickness may be more or less than intended and may vary considerably (680 μm) using a specific microkeratome.