

# Retreatment by Lifting the Original Laser in Situ Keratomileusis Flap after Eleven Years

Hassan Hashemi, MD<sup>1,2</sup> • Mehrdad Mohammadpour, MD<sup>3</sup>

---

---

## Abstract

**Purpose:** To describe a case of successful laser in situ keratomileusis (LASIK) retreatment over a previous LASIK surgery after 11 years

**Case report:** The patient had his first LASIK for the correction of -2.25 -1.75×90° and -2.25 -1.00×90° in the right and left eye, respectively. Eleven years later, the refraction in the right eye was plano -3.25×80° and he was scheduled for an enhancement procedure by relifting the old LASIK flap. Ablation was made with the Allegretto Concerto excimer laser.

**Results:** Three months postoperatively, the right eye uncorrected visual acuity (UCVA) was <sup>20</sup>/<sub>20</sub>, the refraction was plano -0.50×160°, the flap was intact, and the cornea was clear. One year after retreatment the refraction was stable and there was no sign of epithelial ingrowth.

**Conclusion:** LASIK retreatment can be safely performed by lifting the original flap even more than one decade after primary operation provided that the residual stromal bed is adequate.

**Keywords:** Laser in Situ Keratomileusis, Retreatment, Lifting, Original Flap

*Iranian Journal of Ophthalmology 2011;23(2):60-64 © 2011 by the Iranian Society of Ophthalmology*

---

---

## Introduction

Laser in situ keratomileusis (LASIK) has become the most popular surgical technique for correcting myopia and myopic astigmatism for several advantages including the ease and accuracy of retreatment following LASIK. Retreatment may be performed by lifting or recutting the flap and performing the excimer laser ablation on the remaining stromal tissue in cases with adequate residual stromal bed<sup>2,3</sup> or by surface ablation<sup>4,5</sup> which may lead to postoperative corneal haze and is better to be

preserved for patients with thin cornea or inadequate residual stromal bed for retreatment.

Herein, we report an uneventful lifting of the LASIK flap for retreatment of myopic astigmatism eleven years after the primary surgery. To the best of our knowledge, this is the longest period between the original flap creation and successful flap lifting for retreatment.

---

1. Noor Ophthalmology Research Center, Noor Eye Hospital

2. Professor of Ophthalmology, Eye Research Center, Farabi Eye Hospital, Tehran University of Medical Sciences

3. Assistant Professor of Ophthalmology, Eye Research Center, Farabi Eye Hospital, Tehran University of Medical Sciences

Received: September 27, 2010

Accepted: May 8, 2011

Correspondence to: Hassan Hashemi, MD

Noor Ophthalmology Research Center, Noor Eye Hospital, Tehran, Iran, Tel: +98 21 88651515, Email: hhashemi@noorvision.com

Professor of Ophthalmology, Eye Research Center, Farabi Eye Hospital, Tehran University of Medical Sciences

## Case report

A 28-year-old man was referred in September 1995 for refractive surgery. His systemic preoperative examinations were unremarkable. His ocular examinations including slit-lamp intraocular pressure (IOP) and fundus examinations were normal. His subjective refraction was  $-2.25-1.75 \times 90^\circ$  in the right and  $-2.25-1.00 \times 90^\circ$  in the left eye with best corrected visual acuity (BCVA) of  $^{10}/_{10}$  in both eyes. He did not use to wear contact lenses and his refractive error was unchanged since 2 years ago. His topography was compatible with orthogonal symmetric against-the-rule astigmatism. However, one can easily notice that the patient had significant lenticular astigmatism (approximately one Diopter) in both eyes as the subjective refractive astigmatism ( $-1.75$  Diopter/OD and  $-1.00$  Diopter /OS) was higher than the corneal astigmatism ( $0.6$  Diopter /OD and  $0.12$  Diopter /OS) (Figure 1).

He underwent LASIK for both eyes with automated corneal shaper (ACS) microkeratome (Bausch & Lomb, Rochester, New York, USA) with intended flap thickness of  $160 \mu\text{m}$  with a nasal hinge. Summit Plus Apex broad beam excimer laser machine (Summit Technology Inc, California, USA) was then used for laser ablation with optical zone of  $5 \text{ mm}$  and transition zone of  $1 \text{ mm}$  by the author in February 1996. His postoperative period was uneventful except mild increase in the IOP ( $23 \text{ mmHg}$  in the right and  $20 \text{ mmHg}$  in the left eye 45 days after surgery) that seemed to be steroid induced. Hence, the steroid drop was discontinued and the IOP returned to normal values. At that time (postoperative day #45) the uncorrected visual acuity (UCVA) was  $^6/_10$  in the right and  $^{10}/_{10}$  in the left. His BCVA was  $^{10}/_{10}$  in the right eye with  $+0.50- 2.00 \times 90^\circ$  and  $^{10}/_{10}$  in the left eye with  $+0.50- 1.00 \times 90^\circ$ .

Nine months after surgery the UCVA of the right eye was  $^9/_10$  and the BCVA was  $^{10}/_{10}$  with plano  $-1.75 \times 80^\circ$ . The patient did not refer until 11 years after operation in July 2007 due to

decreased vision in the right eye. On examination, his UCVA was  $^3/_10$  in the right eye and  $^8/_10$  in the left eye and the BCVA was  $^{10}/_{10}$  with plano  $-3.00 \times 80^\circ$  and plano  $-1.25 \times 85^\circ$ , respectively. The post-LASIK Orbscan showed astigmatism in both eyes ( $2.20 \text{ D} \times 88^\circ$  in the right and  $0.8 \text{ D} \times 85^\circ$  in the left eye). His central corneal thickness was  $577 \mu\text{m}$  in both eyes by the Orbscan pachymetry and  $577 \mu\text{m}$  and  $569 \mu\text{m}$  by ultrasound pachymetry in the right and left eyes, respectively. There was no sign of post-LASIK keratectasia on ocular examinations or corneal imaging (Figures 2-4).

He was scheduled for reoperation on the right eye by lifting the LASIK flap. In November 2007 he underwent an uneventful lifting of the previous LASIK flap performed by a Sinsky hook to delineate the edge of the flap and raising its edge. Then an enhancement spatula peeled back the cut circumference and proceeded to the nasal hinge to lift the flap. Then the flap was lifted with two flap forceps. Excimer laser ablation was performed with the Allegretto Concerto excimer laser (Wave Light Laser Technology, Germany) for a correction of plano  $-3.25 \times 80^\circ$  by a modern flying spot excimer laser machine with optical zone of  $6.5 \text{ mm}$  and transition zone of  $1.25 \text{ mm}$  with intended stromal ablation of  $49.10 \mu\text{m}$ , presumed LASIK flap of  $160 \mu\text{m}$  and residual stromal thickness of  $367 \mu\text{m}$  by the same surgeon (the author). On the first postoperative day examination, the flap was intact with small striae in its nasal side. Two weeks after the surgery the UCVA of the right eye was  $^9/_10$  and the subjective refraction was  $+0.50- 0.75 \times 170^\circ$  and the BCVA was  $^{10}/_{10}$  and the flap was intact with no flap wrinkling or inflammation. Three months after the reoperation, in February 2008, the UCVA of the right eye was  $^{10}/_{10}$ , the refraction was plano  $-0.50 \times 160^\circ$  and the flap was intact and the cornea was clear.

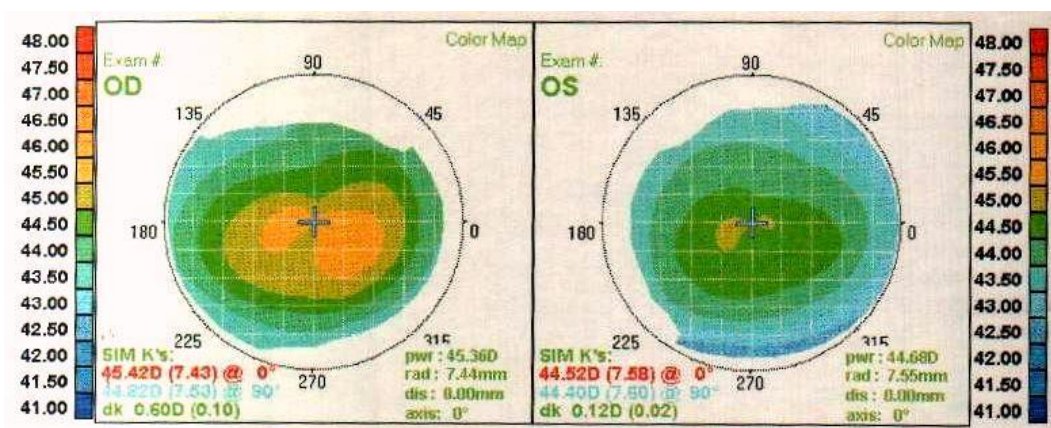


Figure 1. Preoperative topography of both eyes (before the original surgery)

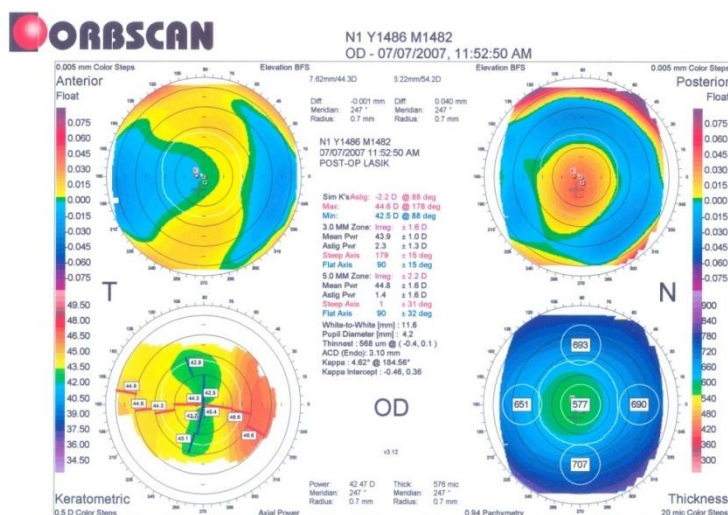


Figure 2. Orbscan of the right eye before retreatment

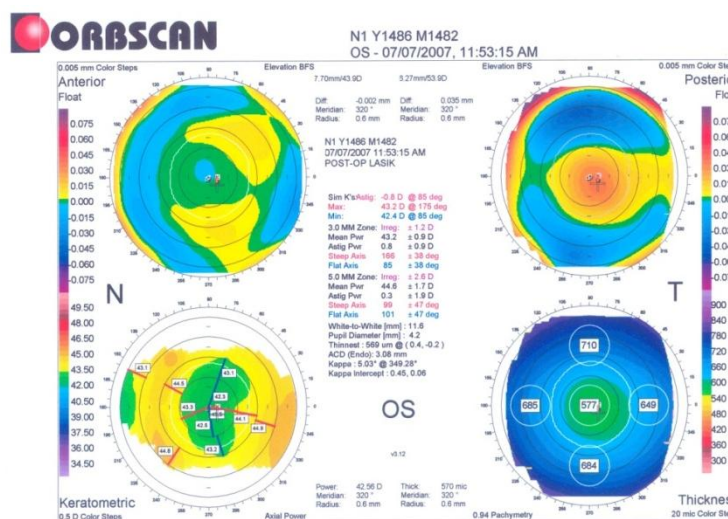


Figure 3. Orbscan of the left eye before retreatment

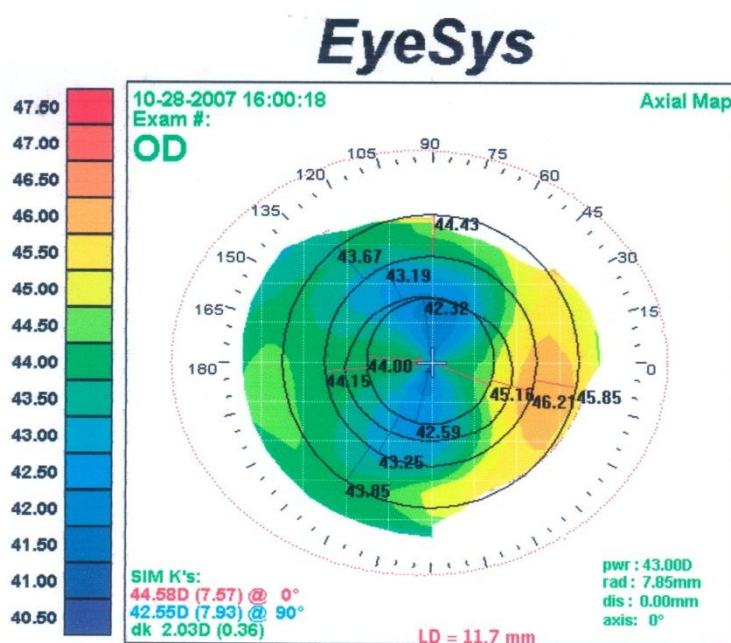


Figure 4. Topography of the right eye before retreatment

## Discussion

LASIK is the most common refractive surgery all over the world<sup>1</sup>; however, its main disadvantages are under correction and regression which can be properly corrected by retreatment provided sufficient corneal thickness. Flap problems and decentered ablations are causes of early postsurgical residual refractive error. However, regression usually occurs late after surgery. Several mechanisms have been mentioned to cause regression after LASIK including ectasia, corneal hydration, stromal synthesis and compensatory epithelial hyperplasia. Both under correction and regression of astigmatism are more probable than simple myopia.<sup>2</sup>

Although this case was treated in the era of broad beam excimer lasers, the myopic component was properly treated after primary surgery but the astigmatic component was under corrected and even increased during eleven years following surgery. The lenticular astigmatism was stable during these years (one diopter).

Lifting the original LASIK flap is the most common and safe method for LASIK retreatment provided adequate residual stromal bed.<sup>1</sup> There are many reports of lifting the flap for LASIK retreatment.<sup>1-8</sup>

It can be performed by a Sinsky hook to delineate the flap edges and lifting it gently by two forceps after undermining with a fine spatula.

Potential problems associated with lifting flaps, specially the old ones, include an increased risk for epithelial ingrowth, diffuse lamellar keratitis, flap tearing and higher rate of striae formation.<sup>1,3</sup>

Recutting the LASIK flap is an alternative way for retreatment and is performed when the flap lifting is not convenient, however, it should be done at a deeper level than the original flap and has several inherent complications including fragmented or transected flaps, epithelial ingrowth, loss of the BCVA, and irregular astigmatism.<sup>1,2</sup>

With both techniques, there is a potential risk for exceeding the safe range for stromal thickness and the development of ectasia.<sup>1,4</sup>

Retreatment should be undertaken only when the refraction has been stabilized by 2 stable manifest refractions 3-4 weeks apart

and is usually performed 4-12 weeks after the primary surgery.<sup>2</sup> The meantime to enhancement has been reported from one month<sup>2</sup> up to 5 years<sup>1</sup> after primary LASIK, however, some authors<sup>6,7</sup> recommend

retreatment at least 6 months after surgery to be sure that the refraction is stabilized and the risk of post-LASIK ectasia is negligible.

Some authors<sup>1,2</sup> apply contact lenses after retreatment and remove it on the following day. However, a recent study reported an increased incidence of epithelial ingrowth with use of an overnight bandage contact lens.<sup>8</sup> They recommended Pinelli spatula to reduce the trauma to the epithelium at the flap edge. The incidence of epithelial ingrowth was not related to the preoperative spherical equivalent, however, increasing age may be considered as a possible risk factor.<sup>8</sup> The author did not use a bandage contact lens after retreatment.

An alternative way for patients with borderline residual stromal bed and limited intended refractive correction is surface ablation by laser assisted subepithelial keratectomy (LASEK) or photorefractive keratectomy (PRK) to treat residual refractive errors on LASIK flap.<sup>5</sup> Recently corneal wave front-guided LASIK retreatment for correction of highly aberrated corneas is recommended following refractive surgery.<sup>6</sup> Sources that may influence the aberrometric pattern of the operated eye by LASIK are changes in corneal biomechanics caused by excimer

laser ablation, flap creation, postoperative wound healing, and tear film changes that might induce optical changes in the corneal properties and hence in the aberrations. All of these changes are exaggerated when complications such as flap problems or decentered ablation occur during the surgical procedure. In this case a conventional treatment with a modern flying spot laser machine, Wavelight Allegerto CONCERTO, was applied for enhancement as the corneal astigmatism was fairly regular and the previous ablation was centered and acceptable (Figures 2, 4). The early refractive outcomes 3 months after reoperation showed UCVA of  $^{10}/_{10}$  with a negligible objective refractive error.

### Conclusion

In conclusion, lifting the flap can be performed even after more than one decade. It seems that the attachment between the LASIK flap and the stromal bed would never recover to the preoperative level as the flap could be easily lifted even eleven years following primary surgery. However, more cases should be tried to reach a more definite and logistic conclusion.

### References

1. Netto MV, Wilson SE. Flap lift for LASIK retreatment in eyes with myopia. *Ophthalmology* 2004;111(7):1362-7.
2. Brahma A, McGhee CN, Graig JP, et al. Safety and predictability of laser in situ keratomileusis enhancement by flap reelevation in high myopia. *J Cataract Refract Surg* 2001;27(4):593-603.
3. Mulhern MG, Condon PI, O'Keefe M. Myopic and hyperopic laser in situ keratomileusis retreatment: indications, techniques, limitations, and results. *J Cataract Refract Surg* 2001;27(8):1278-87.
4. Beerthuizen JJ, Siebelt E. Surface ablation after laser in situ keratomileusis: retreatment on the flap. *J Cataract Refract Surg* 2007;33(8):1376-80.
5. Cagil N, Aydin B, Ozturk S, Hasiripi H. Effectiveness of laser-assisted subepithelial keratectomy to treat residual refractive errors after laser in situ keratomileusis. *J Cataract Refract Surg* 2007;33(4):642-7.
6. Alió J, Galal A, Montalbán R, Piñero D. Corneal wavefront-guided LASIK retreatments for correction of highly aberrated corneas following refractive surgery. *J Refract Surg* 2007;23(8):760-73.
7. Ortega-Usobiaga J, Cobo-Soriano R, Llovet F, et al. Retreatment of hyperopia after primary hyperopic LASIK. *J Refract Surg* 2007;23(2):201-5.
8. Chan CC, Boxer Wachler BS. Comparison of the effect of LASIK retreatment techniques on epithelial ingrowth rates. *Ophthalmology* 2007;114(4):640-2.