

Radiation cataract: Clinicopathologic report

Mehrdad Mohammadpour, MD, Zahra Ebadi Movahedan, Mahmoud Jabbarvand, MD, Hassan Hashemi, MD

We report the case of a 52-year-old woman who developed bilateral anterior and posterior subcapsular cataracts with anterior capsule fibrosis 12 years after exposure to intensive radiation therapy. The woman had uneventful cataract surgery and gained 20/20 corrected distance visual acuity in both eyes. Hematoxylin–eosin staining of the anterior capsule revealed significant subcapsular scar formation in the context of fibroblast proliferation.

Financial Disclosure: No author has a financial or proprietary interest in any material or method mentioned.

J Cataract Refract Surg 2013; 39:285–288 © 2013 ASCRS and ESCRS

Cataract is the leading preventable cause of blindness worldwide.¹ The lens of the eye is one of the most radio-sensitive tissues in the human body. Radiation-induced cataract was reported in an experimental animal within 1 year of Roentgen's discovery of x-rays.^{2,3}

Cataract can be classified by anatomic location as nuclear, cortical, posterior subcapsular, or mixed. However, the main ocular complication related to irradiation is posterior subcapsular cataract. The lens opacification is thought to be started by radiation damage to the lens epithelium around the equator, with DNA damage to the nucleus resulting in abnormal differentiation of the elongating fibers and migration into the posterior subcapsular area.⁴ The latency period—time between irradiation and the appearance of lens opacities—varies. Radiation-induced cataracts develop with greatest frequency 6 months to 1 year after injury; however, late-onset cataracts can be caused by ionizing radiation up to 35 years after exposure.⁵

We report a case of bilateral radiation cataract with anterior subcapsular fibrosis as a rare manifestation of irradiation cataract. We also report the histopathologic evaluation of the anterior capsule, showing the thickening associated with intense fibroblast proliferation.

Submitted: August 18, 2012.

Final revision submitted: October 29, 2012.

Accepted: October 29, 2012.

From the Ophthalmology Department and Eye Research Center, Farabi Eye Hospital, Tehran University of Medical Sciences, Tehran, Iran.

Corresponding author: Mehrdad Mohammadpour, MD, Eye Research Center, Farabi Eye Hospital, Tehran University of Medical Sciences, Tehran, Iran. E-mail: mahammadpour@yahoo.com.

CASE REPORT

A 52-year-old woman with a history of radiotherapy for a jaw tumor was referred to Farabi Hospital, Tehran, Iran. She had a history of progressive painless loss of vision in both eyes starting 10 years previously. Approximately 12 years earlier, she received 10 sessions of x-ray radiation with a total dose of 5 Gy to manage the tumor. On presentation, the uncorrected distance visual acuity (UDVA) was 20/400 in the right eye and 20/160 in the left eye. The slitlamp examination revealed anterior and posterior subcapsular opacities in both eyes, with extensive opacification in the right eye compared with the left eye (Figures 1 and 2). Intraocular pressure (IOP) was 16 mm Hg in both eyes. Other examination of the anterior and posterior segments were unremarkable.

Cataract extraction (sutureless clear corneal phacoemulsification) with intraocular lens implantation was performed sequentially under topical anesthesia in the right and left eyes within a 2-week interval. The procedures were uneventful. During surgery, the anterior capsulorhexis was performed first with a bent 27-gauge needle and then continued with a capsule forceps. The anterior capsulorhexis tissue obtained during surgery was sent for histopathological evaluation. One week postoperatively, the UDVA increased to 20/20 in both eyes. The cornea was clear, the anterior chamber was deep, and a good red reflex was noted (Figure 3). The retinal examination was unremarkable, and the IOP was 12 mm Hg.

Histopathologic Examination

Hematoxylin–eosin staining of the anterior capsules with a magnification of $\times 100$ revealed significant thickening of the capsules in the context of subcapsular scar formation consisting of intense fibroblast proliferation (Figure 4).

DISCUSSION

Cataracts induced by ionizing radiation (eg, x-rays and gamma rays) are usually observed in the posterior region of the lens, often in the form of a posterior subcapsular cataract. Increasing the dose of ionizing radiation causes increasing opacification of the lens, which appears after a decreasing latency period.

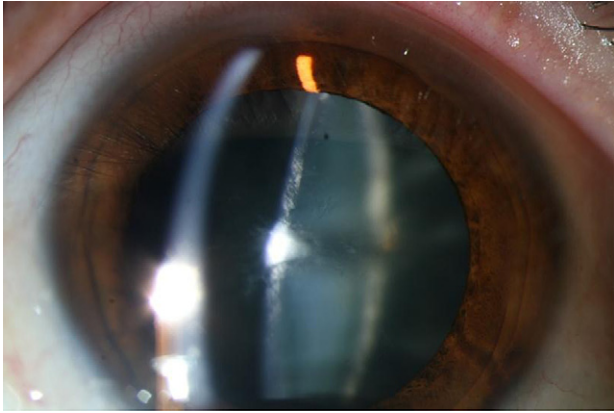


Figure 1. Slitlamp biomicroscopy showing an anterior subcapsular cataract following radiation hazard.

Cataractogenesis induced by ionizing radiation is associated with damage to the lens cell membrane. Another possible mechanism is damage to lens cell DNA, with a decrease in the production of protective enzymes and in sulfur-sulfur bond formation, and altered protein concentrations.⁶

The lens is recognized as one of the most radiosensitive tissues in the human body, and it is known that cataracts can be induced by acute doses of less than 2 Gy of ionizing radiation and less than 5 Gy of protracted radiation. Although much work has been carried out in this area, the exact mechanisms of radiation cataractogenesis are not fully understood. In particular, the question of the threshold dose for cataract development has not been determined. Cataracts have been classified as a deterministic effect of radiation exposure with a threshold of approximately 2 Gy. Some studies indicate that the threshold for cataract development is less than previously estimated, on the order of 0.5 Gy, or that radiation

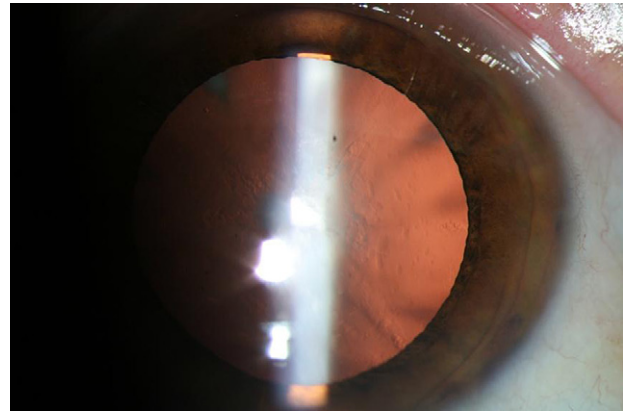


Figure 2. Retroillumination on slitlamp biomicroscopy showing an anterior subcapsular cataract following radiation hazard.

cataractogenesis may be more accurately described by a linear, no-threshold model. The International Commission on Radiological Protection published threshold values for detectable opacities of 5 Sv for chronic exposure and 0.5 to 2.0 Sv for acute exposure. This was also supported by the United States National Council on Radiation Protection and Measurements, which published reported threshold values for visually disabling cataracts of 2 to 10 Sv for single brief exposures and of more than 8 Sv for protracted exposures.³⁻⁷

Damage to DNA has also been described in the human cataractous lens epithelium, and oxidative stress generated by all kinds of radiation and endogenous metabolic processes has been suggested as playing a significant role in the pathogenesis of cataract. Single and fractionated doses of gamma radiation induced lens crystallin changes that might lead to the development of cataract due to induction of crosslinking and aggregation. The β_H -crystallin was the most stable against radiation-induced damage, and the molecular




Figure 3. Slitlamp biomicroscopy showing the anterior segment view on the first postoperative day.

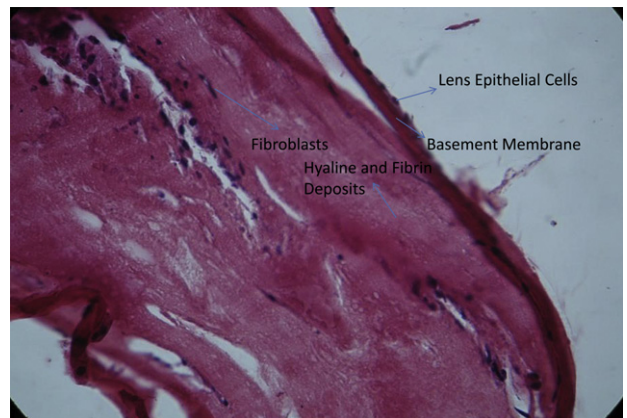


Figure 4. Histopathological evaluation showing significant subcapsular scar formation consisting of fibroblast proliferation and hyaloid production over the basement membrane of the anterior capsule following radiation cataract.

weight of gamma crystallin was the most sensitive to gamma radiation.⁷

Significant exposure to radiation always causes posterior subcapsular cataracts⁵; however, no evidence has demonstrated an anterior subcapsular cataract subsequent to radiation injury. It is also noteworthy that capsulorhexis in cases with severely fibrotic anterior capsule is very difficult and requires more time, skill, and attention to perform.⁸

One study evaluated the long-term histological development of radiation-induced ocular injury secondary to megavoltage radiotherapy for naturally occurring tumors in animals.⁶ In humans, the latency period for clinical detection of radiation-induced cataracts varies from 6 months to 35 years, with an average period of 2 to 4 years.⁹ The time from the start of cataract formation to the time of diagnosis is also variable and depends on the rate of cataract progression, type and localization of the cataract, and personal needs for clear vision. Therefore, the exact time of development of a cataract following ionizing radiation cannot be determined. In our case, the surgery was performed 12 years after radiation therapy; however, there had been no ocular examination within this period to indicate the exact date of cataract formation.

The pathogenesis of radiation cataracts is thought to be deformation of heat-labile enzymes, for example glutathione peroxidase, that ordinarily protect lens cell proteins and membrane lipids from oxidative impairment. Oxidation of protein sulfhydryl groups and the development of high molecular weight aggregates cause variations in the orderly structure of cells. A complementary pathophysiologic mechanism is thermoelastic expansion through which pressure waves in the aqueous humor cause direct physical damage to the lens cells. Cataracts induced by radiation (eg, x-rays and gamma rays) are usually localized in the posterior territory of the lens, often in the form of a posterior subcapsular cataract,¹⁰ although in our case radiation cataract presented in a mixed mode in the anterior and posterior parts of the lens and also manifested as fibrosis of the anterior capsule.

Thyroid-related immune orbitopathy is an important indication of radiotherapy that may cause cataracts sometimes associated with glaucoma.¹¹ However, our patient did not mention any relevant history.

Significant postoperative inflammation is usually present in cases with cataract in the context of prior uveitis or trauma.^{12,13} However, the uneventful postoperative course in our patient suggests that cataract formation after radiation exposure may not be associated with significant inflammation.

We previously reported a case with bilateral electric cataracts with anterior capsule fibrosis on histological examinations and presumed that severe

anterior capsule fibrosis might cause nutrition defects and subsequent cataracts.¹² This presumption seems logical in this case with ionizing radiation cataract.^{14,15}

In our case, the postoperative visual rehabilitation in both eyes was good. It suggests that the surgical results and visual rehabilitation after cataract surgery in patients with radiation cataract without other ocular damage is favorable. We concluded that the cataracts seen in the present study were a late complication of radiation cataract with the rare manifestation of fibrosis of the subanterior capsule.

REFERENCES

1. Mirdehghan SA, Dehghan MH, Mohammadpour M, Heidari K, Khosravi M. Causes of severe visual impairment and blindness in schools for visually handicapped children in Iran. *Br J Ophthalmol* 2005; 89:612–614. Available at: <http://www.ncbi.nlm.nih.gov/pmc/articles/PMC1772642/pdf/bjo08900612.pdf>. Accessed November 11, 2012
2. Chalupceky H. Ueber die Wirkung der Röntgenstrahlen. In: Hirschberg J, ed, *Centralblatt für praktische Augenheilkunde*. Leipzig, Germany, Veit & Comp., 1897; 386–401
3. Vano E, Kleiman NJ, Duran A, Rehani MM, Echeverri D, Cabrera M. Radiation cataract risk in interventional cardiology personnel. *Radiat Res* 2010; 174:490–495
4. Wilde G, Sjöstrand J. A clinical study of radiation cataract formation in adult life following γ irradiation of the lens in early childhood. *Br J Ophthalmol* 1997; 81:261–266. Available at: <http://bj.o.bmj.com/content/81/4/261.full.pdf>. Accessed November 11, 2012
5. Chodick G, Bekiroglu N, Hauptmann M, Alexander BH, Freedman DM, Doody MM, Cheung LC, Simon SL, Weinstock RM, Bouville A, Sigurdson AJ. Risk of cataract after exposure to low doses of ionizing radiation: a 20-year prospective cohort study among US radiologic technologists. *Am J Epidemiol* 2008; 168:620–631. Available at: <http://www.ncbi.nlm.nih.gov/pmc/articles/PMC2727195/pdf/kwn171.pdf>. Accessed November 11, 2012
6. Lipman RM, Tripathi BJ, Tripathi RC. Cataracts induced by microwave and ionizing radiation. *Surv Ophthalmol* 1988; 33:200–210
7. Ainsbury EA, Bouffler SD, Dörr W, Graw J, Muirhead CR, Edwards AA, Cooper J. Radiation cataractogenesis: a review of recent studies. *Radiat Res* 2009; 172:1–9
8. Mohammadpour M, Erfanian R, Karimi N. Capsulorhexis: pearls and pitfalls. *Saudi J Ophthalmol* 2012; 26:33–40. Available at: <http://download.journals.elsevierhealth.com/pdfs/journals/1319-4534/PIIS1319453411001275.pdf>. Accessed November 11, 2012
9. Behrouzi Z, Rabei HM, Azizi F, Daftarian N, Mehrabi Y, Ardeshiri M, Mohammadpour M. Prevalence of open-angle glaucoma, glaucoma suspect, and ocular hypertension in thyroid-related immune orbitopathy. *J Glaucoma* 2007; 16:358–362
10. Mohammadpour M, Jafarinasab MR, Javadi MA. Outcomes of acute postoperative inflammation after cataract surgery. *Eur J Ophthalmol* 2007; 17:20–28
11. Javadi M-A, Jafarinasab M-R, Araghi A-AS, Mohammadpour M, Yazdani S. Outcomes of phacoemulsification and in-the-bag intraocular lens implantation in Fuchs' heterochromic iridocyclitis. *J Cataract Refract Surg* 2005; 31:997–1001

12. Hashemi H, Jabbarvand M, Mohammadpour M. Bilateral electric cataracts: clinicopathologic report. *J Cataract Refract Surg* 2008; 34:1409–1412
13. Ching SV, McChesney Gillette S, Powers BE, Roberts SM, Gillette EL, Withrow SJ. Radiation-induced ocular injury in the dog: a histological study. *Int J Radiat Oncol Biol Phys* 1990; 19:321–328
14. Abdelkawi S. Lens crystallin response to whole body irradiation with single and fractionated doses of gamma radiation. *Int J Radiat Biol* 2012; 88:600–606
15. Blakely EA, Kleiman NJ, Neriishi K, Chodick G, Chylack LT, Cucinotta FA, Minamoto A, Nakashima E, Kumagami T, Kitaoka T, Kanamoto T, Kiuchi Y, Chang P, Fujii N, Shore RE.

Radiation cataractogenesis: epidemiology and biology. *Radiat Res* 2010; 173:709–717



First author:

Mehrdad Mohammadpour, MD

*Eye Research Center, Farabi Eye
Hospital, Tehran University of Medical
Sciences, Tehran, Iran*